



5th Advanced Course in Knee surgery
February 2nd -7th, 2014
Val d'Isère - France

Quadriceps tendinopathy

Mike Carmont
President BOSTAA
Princess Royal Hospital, Telford
Northern General Hospital, Sheffield
United Kingdom





Princess Royal Hospital, Telford




Definitions

- Painful thickened dysfunctional tendon
- Tendinopathy: condition
- Tendinosis: pathological structural change
- Paratendinopathy: Inflammation of tissues surrounding tendon
- Tendinitis: inflammatory arthropathy

Maffulli N, Khan KM, Puddu G: Overuse tendon conditions: time to change a confusing terminology. *Arthroscopy* 1998;14:840-843

Anatomy

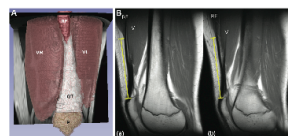
- Quadriceps tendon confluence & surrounds tendon
 - Vastus Medialis
 - Vastus Lateralis
 - Vastus Intermedius
 - Rectus Femoris
- Length 50mm+/-9mm
- Thickness 8mm+/-1mm
- Insertion 18mm+/-3mm



Staeubli AJR 1999;173(3):691-8

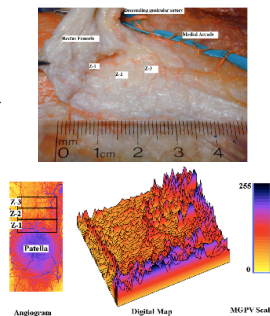
Anatomy

- MRI study- supr pole to the most infr aspect rectus femoris
- Length
 - Males 81.1mm
 - Females 73.5mm
- Thickness
 - 7.37mm at 10mm
 - 15% cadaveric specimens typical pattern
- 87.5% greater than patella
 - Bilaminar, trilaminar or tetralaminar pattern



Xerogeans AJSM 2013 in press
Waligora. Clinical anatomy of the quadriceps femoris and extensor apparatus of the knee. *Clin Orthop Rel Res* 2009;467:3297-3306

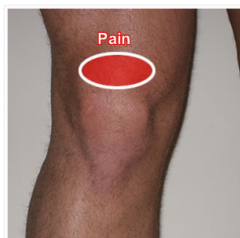- Vascular supply
 - lateral femoral circumflex
 - descending geniculate
 - medial and lateral superior geniculate arteries
- Avascular area deep part tendon 1.5-3cm
- Patella articulates with femur during flexion degenerative changes occur



Petersen W, Stein V, Tillmann B. Blood supply of the quadriceps tendon. *Unfallchirurg* 1999;102:543-7
Yepes H, Tang M, Morris SF, Stanish WD. Relationships between hypovascular zones and patterns of rupture of quadriceps tendons. *JBS Am* 2008;90:2138-41

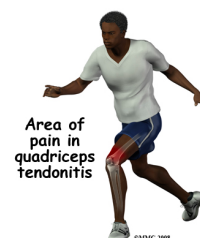Symptoms & signs

- Pain
- During & post exertional
- Localized swelling
- Local tenderness
- Single leg squat decline



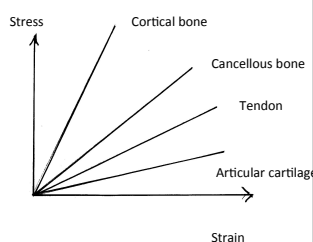
Associated sports activity

- Running
- Jumpers knee



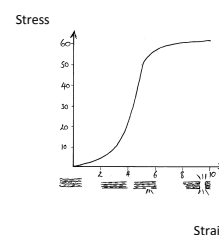
Tendon composition

- 90-95% tenocytes & tenoblasts
- 5-10% chondrocytes
- Synovial cells
- Vascular cells
- Extra-cellular matrix
 - Collagen
 - Elastin
 - Proteoglycans, GAG, Glycoproteins



Quadriceps biomechanical properties

- Elastic modulus 1200-1800 MPa
- UTS 50-100MPa
- Strain 9-35%
- 50-75% fibers severed pre rupture under physiological load
- Tendon degeneration leads to reduced tensile strength



Co-existent medical conditions

- Hyperparathyroidism
- Calcium pyrophosphate deposition
- Diabetes Mellitus
- Steroid induced tendinopathy
- Fluroquinolone induced tendinopathy
- Osteomalacia
- Chronic renal insufficiency
- Gout
- Uraemia

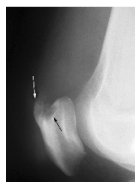Treatment

- Non-operative
 - Eccentric loading exercises
 - Stretching
 - PRP
 - Extra-corporal shock wave therapy
 - High volume injection



Radiographic features

- Superior pole patella erosions
- Patella enthesophytes
- 79% spur
- “Whiskers”
- Intra-tendinous calcification



CASE REPORT

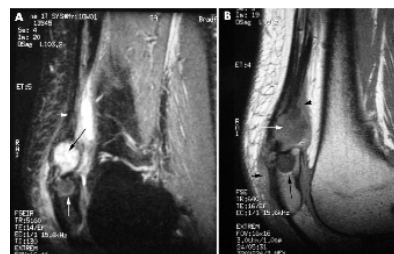
Calcific tendonitis of the quadriceps

B Varghese, G S Radcliffe, C Groves

Br J Sports Med 2005;40:652-654. doi: 10.1136/bjsm.2005.029117

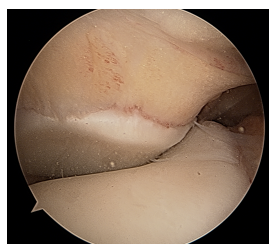
Macurak 1980, Trujeque 1977

MRI



Surgical treatment

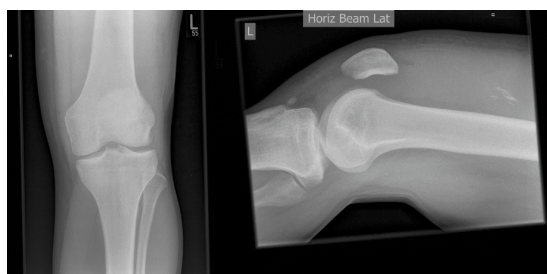- Arthroscopic debridement
- Arthroscopic guided tenotomy
- Open tenotomy
- Reconstruction



Complications

- Calcific
- Rupture
 - >40yrs
 - Unable SLR
 - 38% misdiagnosis
 - Immediate intense tearing sensation
 - Patella baja

Case of calcification



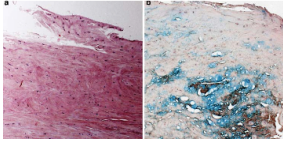
Quadriceps rupture

- 3% all tendon ruptures
- Uncommon 1.37/100000
- Males > females x6
- Majority 50s & 60s
- 88% > 40 yrs
- Eccentric overload
- Arrest fall
- Foot planted knee semi flexed
- Bilateral <5% cases
- Palpable gap
- Supra-patella gap
- Missed diagnosis due intact retinaculum
- Internal rotation of the hip use Sartorius

Knee Surg Sports Traumatol Arthrosc (2010) 18:83–88
 DOI 10.1007/s00137-009-0364-x
KNEE

Histologic analysis of ruptured quadriceps tendons
 Per David Trobisch · Matthias Bauman ·
 Klaus Weise · Fabian Stuby · David J. Hak

- 45 tendons
- 42 patients
- 22 tissue samples
- 64% degeneration
- Degeneration correlated age



Kannus Jozsa Histopathological changes preceding spontaneous rupture of a tendon. A controlled study of 891 patients. J Bone Joint Surg Am 1991;73(10):1507-27


29/891 quadriceps tendons
 All hypoxic area degeneration

International Orthopaedics (ISCOYT) (2012) 36:2367–2371
 DOI 10.1007/s00137-012-1017-x
ORIGINAL PAPER

Light microscopic histology of quadriceps tendon ruptures
 Nicola Maffulli · Angelo Del Buono · Filippo Spierola ·
 Umile Giuseppe Longo · Vincenzo Denaro

- 46 samples tendon post rupture
- 11 controls
- Pathological sum score
- 19.2 rupture
- 5.6 controls
- Abnormal collagen formation
- Increased type III collagen production


Imaging: plane radiographs



Eur J Orthop Surg Traumatol
 DOI 10.1007/s00137-013-1207-x
ORIGINAL ARTICLE

Acute quadriceps tendon rupture: a pragmatic approach to diagnostic imaging
 Joel S. Perfitt · Michael J. Petrie · Chris M. Blundell ·
 Mark B. Davies

- Imaging US vs. MRI
- 66 patients
- Audit mis-diagnosis 9%>5%
- US Sens 1, Spec 0.67 +ve PV 0.88
- MRI Sens 1, Spec 1 +ve PV 1



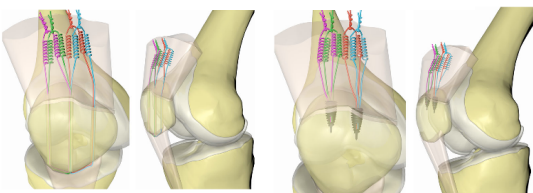
Perfitt JS, Petrie MJ, Blundell CM, Davies MB. Acute quadriceps tendon rupture: a pragmatic approach to diagnostic imaging. Eur J Orthop Surg Traumatol 2013 in press

Treatment options for repair

- Non-operative
 - If extensor retinaculum intact
 - Brace extension
 - ? When to move
- Operative
 - 48-72° Staubli best outcome


Knee Surg Sports Traumatol Arthrosc
 DOI 10.1007/s00137-014-2854-3
KNEE

Suture anchor repair yields better biomechanical properties than transosseous sutures in ruptured quadriceps tendons
 M. Perri · A. Drezatillo · S. Brand · T. Callies ·
 C. Henschler · C. Krettek · M. Jagodzinski ·
 M. Entinger




30 cadaveric knees Titanium and hydroxyapatite anchors vs. transosseous drill holes
 No. 2 Ultrabraid, 250 cycles 20N for 30s
 Less gap formation TA 1.9mm vs. 33.3mm, UTS TA 740, TS 338
 Pull out eyelet, suture rupture

Locking suture: Krackow



Krackow
Stitch



ETHIBOND EXCEL W4846
5
4x75cm

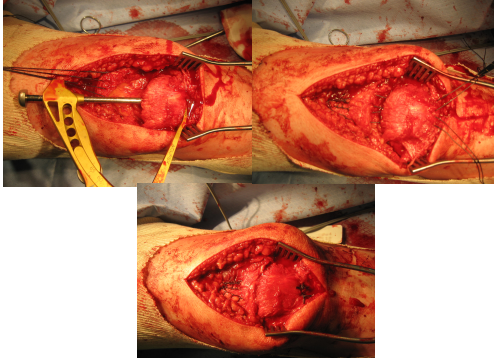
Ultimate Tensile Strength 16N

Krackow. A new stitch for ligament-tendon fixation. Brief note. JBJS Am 1986;68:764-766

Transosseus vs. Anchors

- Lighthart 2008
- No difference
- Hart 2012
- Less UTS
 - Suture anchors 447N
 - Transosseus 591N
- Mode failure eyelet

Repair techniques



Postoperative functional rehabilitation after repair of quadriceps tendon ruptures: a comparison of two different protocols

Romy Langshan · Matthias Baumann · Pedro Ricart · David Hak · Axel Probst · Andreas Bafke · Per Trobbach

- Rehabilitation
- Protection brace
- Early weight bearing
- Early flexion

- 2 groups
- Ltd flexion & Ltd WB
- Early flexion & full WB
- Return to work 10 days earlier

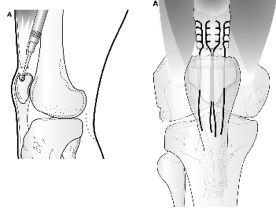


Early Motion After Quadriceps and Patellar Tendon Repairs

Outcomes With Single-Suture Augmentation

Jesse L. West, MD, James S. Keene,* MD, and Lee D. Kaplan, MD
From the Division of Sports Medicine, Department of Orthopedic Surgery and Rehabilitation, University of Wisconsin-Madison, Madison, Wisconsin

- Case series of quadriceps & patella tendons
- 20 Quadriceps
- Krakow suture with transosseous holes & relaxation suture
- No.5 Ethibond
- 8 weeks 120° flexion & brace free ambulation
- Early motion FWB
- 6/12 all pre-injury activity levels



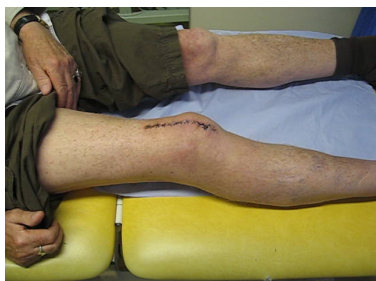Early Motion After Quadriceps and Patellar Tendon Repairs

Outcomes With Single-Suture Augmentation

Jesse L. West, MD, James S. Keene,* MD, and Lee D. Kaplan, MD
From the Division of Sports Medicine, Department of Orthopedic Surgery and Rehabilitation, University of Wisconsin-Madison, Madison, Wisconsin

<ul style="list-style-type: none"> • Commence motion 5-7/7 • Locked brace extension FWB • Removed active flexion 0-55 deg 	<ul style="list-style-type: none"> • 120deg knee flexion • Brace free ambulation • 7.2/52 Quads • 7.7/52 Patella • 6/12 all RTP • 4 yrs Lysholm 92pts
--	---

Early movement



Revision technique

- Autologous hamstring
 - McCormick F, Nwachukwu BU, Kim J, Martin SD. Autologous hamstring tendon used for revision of quadriceps tendon tears. Orthopedics 2013;36(4):e529-32
- Synthetic ligament
 - Rust PA, Tanner N, Spicer DDM. Repair of ruptured quadricep tendon with Leeds Keio ligament following revision knee surgery. KSSTA 2008;16:270-2

Complications

Patellar Stress Fracture After Transosseous Extensor Mechanism Repair

Report of 3 Cases

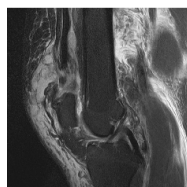
James M. Gregory,* MD, Seth L. Sherman,** MD, Richard Mathier,** MD, and Bernard R. Bach Jr.,** MD
 Investigation performed at the Division of Sports Medicine, Department of Orthopaedic Surgery, Rush University Medical Center, Chicago, Illinois

- Role of foreign body reaction with Fiber wire?
- Tightrope

Quadriceps Tendon Injuries in National Football League Players

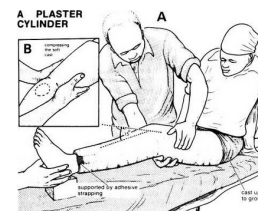
Martin Boublík,* MD, Theodore F. Schlegel,* MD, Ryan C. Koonce,* MD, James W. Genuario,* MD, and Jason D. Kirkartz,** MD
 Investigation performed at Steadman Hawkins Clinic-Denver, Greenwood Village, Colorado

- 10 year period
- 14 cases, Age 27.1yrs
- Eccentric 80%
- Direct blow 20%
- 66% superior pole patella
- 33% just proximal
- 79% reported complete recovery full strength & absence pain
- Only 50% RTP



Post operative management

- *Cylinder cast
- *6/52
- *Difficult to mobilise
- *Resulted
- *Stiff knee
- *Wasted quadriceps
- *Difficult rehabilitation



Siwek & Rao. Ruptures of the extensor mechanism of the knee joint. JBJS Am 1981;63:932-7

Cast immobilisation?

